

## Review

# The neurobiology of Williams syndrome: Cascading influences of visual system impairment?

M. A. Eckert<sup>a,\*</sup>, A. M. Galaburda<sup>b</sup>, D. L. Mills<sup>c</sup>, U. Bellugi<sup>d</sup>, J. R. Korenberg<sup>e</sup> and A. L. Reiss<sup>f</sup>

<sup>a</sup> Department of Otolaryngology-Head & Neck Surgery, Medical University of South Carolina, 135 Rutledge Avenue, P.O. Box 250550, Charleston, SC 29425 (USA), e-mail: eckert@musc.edu

<sup>b</sup> Department of Neurology, Harvard Medical School, Boston, MA (USA)

<sup>c</sup> Department of Psychology, Emory University, Atlanta, GA (USA)

<sup>d</sup> Salk Institute Laboratory for Cognitive Neuroscience, La Jolla, CA (USA)

<sup>e</sup> Department of Pediatrics, UCLA, Los Angeles, CA (USA)

<sup>f</sup> Department of Psychiatry and Behavioral Sciences, Stanford University School of Medicine, Stanford, CA (USA)

Received 17 November 2005; received after revision 16 February 2006; accepted 4 May 2006

Online First 30 June 2006

**Abstract.** Williams syndrome (WS) is characterized by a unique pattern of cognitive, behavioral, and neurobiological findings that stem from a microdeletion of genes on chromosome 7. Visuospatial ability is particularly affected in WS and neurobiological studies of WS demonstrate atypical function and structure in posterior parietal, thalamic, and cerebellar regions that are important for performing space-based actions. This review summarizes the neurobiological findings in WS, and, based on these findings, we suggest that people with WS have a primary impairment in neural systems that support the

performance of space-based actions. We also examine the question of whether impaired development of visual systems could affect the development of atypical social-emotional and language function in people with WS. Finally, we propose developmental explanations for the visual system impairments in WS. While hemizygosity for the transcription factor II-I gene family probably affects the development of visual systems, we also suggest that Lim-kinase 1 hemizygosity exacerbates the impairments in performing space-based actions.

**Keywords.** Williams syndrome, visuospatial, visual spatial, dorsal stream hypothesis, LIMK1, pulvinar.

## Introduction

Hemizygosity for ~28 genes on chromosome 7 (q11.23) produces broad ranging developmental effects that include atypical facial features, cardiac and gastrointestinal anomalies, glucose intolerance, hypertension, strabismus, sensorineural hearing loss, visuospatial impairment, unusual social behavior and increased anxiety [1–5]. Many of these broad ranging effects, such as an impaired acoustic reflex [6], appear to be direct effects of the genetic deletion. Other problems, such as social-emotional

or language difficulties could be indirect consequences of anomalous visual system input into neural systems that support social-emotional and language function. We review neurobiological findings that parallel the visual system problems in people with WS, examine whether anomalous visual system development could influence the affected neural systems that support language and social function, and present testable developmental hypotheses for the neurobiological expression of visuospatial impairment in WS.

This review does not evaluate the entire literature on social and language function in people with WS. Instead, this review examines whether developmental events

\* Corresponding author.

causing the dramatic visuospatial impairments may have indirect effects on aspects of language and social-emotional function because of the interaction of these systems with the visual system. Specifically, we examine whether impaired visual system development could impact the development of systems important for detecting affect in faces, and systems for oral language comprehension because of a failure to integrate visual system information.

### The Williams syndrome cognitive and anatomical profile

Most people with WS have mild to moderate mental retardation, with typically greater deficits in performance than verbal IQ [7–9]. Diminished cognitive ability is consistent with a general decrease in cerebral gray matter (~11%) and white matter volume (~18%) compared with healthy, age- and gender-matched controls [10, 11], although no direct association between variation in WS IQ and brain volume has been demonstrated. The most pronounced reductions occur in occipital and parietal regions relative to frontal regions [10, 12], and may indicate that cortical patterning genes [13] play a role in the developmental neuropathology of WS. For example, the deleted transcription factor *TFII-I* (*TFII-I*) genes could influence cortical patterning in WS because they regulate gooseoid, a homeobox-containing protein that modulates anatomical patterning in vertebrate embryos [14]. Reduced cerebral volume in people with WS is accompanied by unusual gyral/sulcal patterning. Atypical central sulcus [15, 16] and Sylvian fissure patterning has been reported [17]. Increased gyrification also has been observed, particularly in posterior cortical regions [18]. In addition, there is one case report of a 19-month-old WS male who exhibited oligogyric microcephaly or microcephaly with a simplified gyral pattern, particularly in the parietal lobe, where shallow parietal sulci were observed [19]. This is an atypical WS finding [20], but few studies have examined WS infant or early childhood brains.

In addition to reduced cerebral volume and anomalous sulcal patterning, people with WS have unusually shaped brains [21]. In particular, the corpus callosum appears flattened or less concave in mid-sagittal sections compared with control participants [22, 23]. The corpus callosum also is flattened in animals that have not undergone the dramatic frontal and temporal/parietal growth that occurs in humans. Enlarged frontal and temporal/parietal growth could mechanically bend the corpus callosum. Consistent with this notion is the finding that the corpus callosum becomes more rounded with increasing corpus callosum splenium size in both control ( $r_{(40)} = -0.39, p < 0.05$ ) and WS participants ( $r_{(42)} = -0.41, p < 0.01$ ) (Eckert, unpublished observation). One important question to address is whether these findings reflect a specific impairment

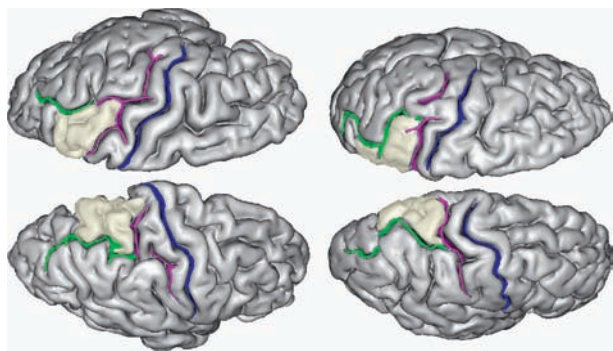
affecting the connectivity of homologous occipital and parietal regions, or reflects anomalous input into occipital and parietal regions, from the pulvinar for example.

### An anomalous visual system

Visual constructive, visual motor, visuospatial working memory, selective attention, and saccadic eye movement abilities are particularly affected in WS [7–9, 24–26]. Surprisingly, the ability to identify objects and faces appears to be a relative cognitive strength in WS [3, 27]. This relative strength, in the context of severe visuospatial impairment, forms the basis for the hypothesis that WS visuospatial impairments stem from developmental problems within the dorsal stream or ‘where’ pathways [3]. Although there is some evidence for atypical function and structure of the ventral stream or ‘what’ pathways [11, 28], functional imaging, structural imaging, and post-mortem studies support the hypothesis for a primary dorsal stream impairment. Based on the evidence published to date and reviewed below, we predict that people with WS have particular deficits in the visual-motor system that limits the ability to perform space-based actions.

Functional imaging studies of WS visuospatial processing show reduced activation in occipital and parietal cortex when WS participants perform object completion [29], object height/positional comparison [29], visual working memory [30], and global attention to shape tasks (Mobbs, unpublished observation). Reduced activation within the intraparietal sulcus during visuospatial tasks is consistent with findings of increased parietal lobe gyrification, voxel- and tensor-based morphometry studies showing decreased parietal gray matter volume [11, 29, 31] or density [10], a shallow intraparietal sulcus [32], and decreased occipital and parietal lobe volumetric measurements in WS adults compared with control adults [10]. These dependable findings implicate posterior parietal regions in the WS visuospatial impairments.

There is some evidence to suggest that anomalous posterior cortical development in people with WS is most pronounced in the superior parietal lobule. Eckert et al. [33] demonstrated that the superior parietal lobule in WS is significantly reduced in volume compared with controls, even after controlling for total cerebral volume. Figure 1 shows a small superior parietal lobule and medially positioned intraparietal sulcus in a representative WS adult compared with a control adult. Post-mortem pathology and histology studies of WS brains also have demonstrated anomalies in the superior parietal lobule or Brodmann area 7. Holinger et al. [34] reported increased neuronal size and greater cell packing density in the superior parietal lobule of five post-mortem WS brains, suggesting the presence of enlarged neuronal bodies and decreased neuropil. These findings provide support for the



**Figure 1.** Cortical and sulcal renderings demonstrate the left and right superior parietal lobules (yellow shading) for a control adult (left) and a WS adult (right). Note the smaller superior parietal lobe in the WS brain and that the intraparietal sulci course (green) more medially in the WS brain. The post-central (pink) and central sulci (blue) have been labeled to provide reference landmarks. Renderings created with BrainVISA/Anatomist ([www.brainvisa.info](http://www.brainvisa.info)).

premise that the visual spatial problems in people with WS stem from anomalous development of systems that direct space-based actions.

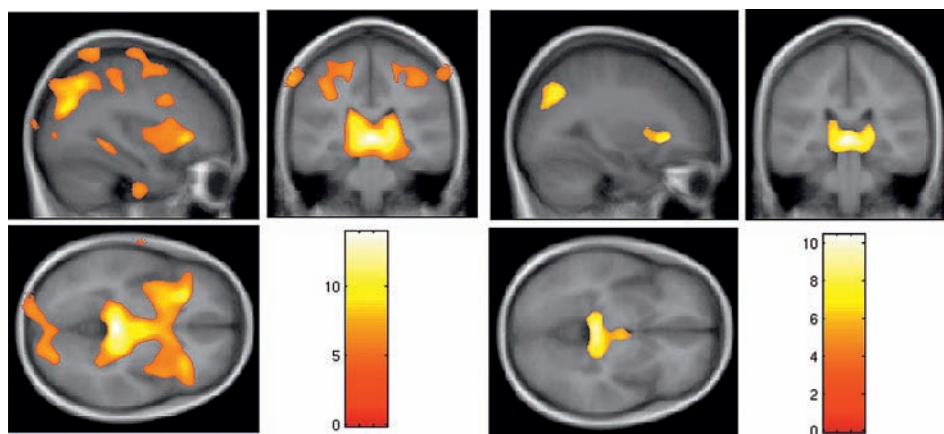
Nuclei within the posterior thalamus contribute to visuo-motor function, and a posterior thalamus impairment is another plausible explanation for problems with space-based actions among people with WS [35]. A voxel-based morphometry study of 42 typical WS adults and 40 control adults demonstrated gray matter reductions in the posterior thalamus [11]. The posterior thalamus, and pulvinar in particular, is critical for visuospatial tasks [36] and feature binding [37]. Feature binding is represented by electrophysiological gamma band activity, and, in the cat, this activity is modulated by pulvinar function [38, 39]. Grice et al. [40] reported that a group of eight

WS adults failed to exhibit clear gamma band activity when viewing faces. The authors suggested that aberrant gamma bursts may reflect impairments in feature binding and that these findings reflect atypical neuroanatomical development. Although speculative, this finding is consistent with anomalous pulvinar development or function in WS.

Reduced hypothalamus gray matter volume, but not thalamus gray matter volume, was observed by Meyer-Lindenberg et al. [29] in high functioning WS adults. We replicated this hypothalamus finding in a small sample of WS adults and controls using the Meyer-Lindenberg methodology [41]. We further determined that this finding was related to gross shape/volumetric differences in the midbrain between the groups. Figure 2 shows that this shape/volumetric difference is focused in the thalamus for the larger sample of 42 WS and 40 controls.

The cerebellar vermis is another component of the visual-motor system where developmental impairment could result in difficulty with space-based actions. This region plays a critical role in saccadic eye movements [42, 43], which are disturbed in people with WS [26]. Individuals with WS also have a disproportionately large cerebellum [44–47], particularly the cerebellar vermis. Schmitt et al. [46] compared the vermis of 20 WS adults and 20 control adults. Lobules VI-X were significantly larger in WS adults compared with the controls after adjusting for global effects of brain volume.

Anomalous functional and structural features throughout visuospatial, visuoconstructive, and visuomotor systems have been observed in imaging studies of WS. The superior parietal lobe, posterior thalamus, and vermis findings suggest a particular impairment in visual systems



**Figure 2.** The left set of three images and right set of three images present voxel-based morphometry results for brain regions where 40 control adults have more gray matter volume than 42 WS adults. The left set of three images includes results before correcting for cerebral gray matter volume (FWE  $p < 0.05$ ). The right set of three images includes results after correcting for cerebral gray matter volume (FWE  $p < 0.05$ ). The color bars indicate the level of significance in t-scores. Note that the gray matter findings are much more widespread before controlling for cerebral gray matter volume, and that they have a C-shaped appearance in the diencephalon. The most robust differences are in the posterior thalamus, posterior parietal lobe, and the intersection between the insula and the inferior frontal gyrus. The image processing to produce these results was consistent with the Meyer-Lindenberg et al. [29] processing strategy. This approach differs from the approach used for the Reiss et al. [24] voxel-based morphometry analyses, but yields similar group differences.

critical for performing space-based actions. We predict that techniques such as diffusion tensor imaging will demonstrate dramatic reductions in the number of white matter fibers connecting the superior parietal lobule and the posterior thalamus.

One important question to address is whether these findings are a primary cause of visual system problems or a consequence of anomalous development elsewhere in the visual system. For example, Galaburda et al. [48] observed more small and fewer large layer IV neurons in a post-mortem WS study primary visual cortex. This finding raises questions about the specificity of the WS developmental lesion to the dorsal stream.

### Cascading developmental effects?

Fundamental developmental questions in the study of WS include the specificity of linkage between deleted genes to atypical neural development, and whether atypical development of one neural system has consequences to the development of other functionally associated systems. Behavioral and neurobiological evidence suggest that some of the social-emotional and language deficits in people with WS could be attributed to primary visual system impairments. The next section examines whether there is validity to the premise that social-emotional and language deficits reflect a failure of neural systems to properly integrate visual system information.

### Social neuroscience

In view of prominent visual deficits, the relative proficiency of people with WS in face recognition is surprising [49]. Face processing in people with WS is not normal, however. An event-related potential (ERP) study by Mills et al. [50] showed abnormal brain activity during recognition of upright and inverted faces. Adults with WS showed (1) an abnormally small N1, a possible sign of decreased activity in primary visual cortex in WS, and (2) an abnormally large N200 linked to accuracy, which could reflect increased attention to faces. Furthermore, in contrast to controls, who showed marked differences in the timing, polarity and distribution of a match-mismatch effect for upright *versus* inverted faces, adults with WS showed a similar match-mismatch effect for both upright and inverted faces.

Face recognition proficiency and ERP anomalies when viewing faces are consistent findings when considered in the context of a study by Thomas et al. [51]. This study showed that face recognition is not impaired in WS adults when analysis of general face configuration is required, but is impaired when face processing requires estimating distances from facial features. Difficulty in-

tegrating the relative position of facial features, because of eye movement problems, a poor representation of visual space, and/or feature binding problems, may explain poor WS performance for a face recognition task that requires an estimation of distances between facial features.

Despite a relative strength in facial recognition, detection of negative facial affect has been reported to be poor compared with detecting positive affect in people with WS [52], and compared with typically developing controls [53]. Observing changes in the 'whites of the eyes' and the 'eye brow frown' are important for detecting fear [54] and anger [55], respectively. Our ability to more rapidly detect threatening 'eye brow frowns' than non-threatening eye brow positions is dependent on configural features of the entire face [55], however, and multiple facial features contribute to detection of face affect [56]. For this reason, difficulty estimating the distance between facial features that result in impaired detection of face affect is one example for how visual system impairment could have downstream effects on the development of neurobehavioral systems critical for social-emotion and social-cognition. More specifically, since the pulvinar has direct input into the amygdala during implicit recognition of negative affect in faces [57], anomalous pulvinar development could affect the development of implicit detection of emotion by the amygdala.

Alternatively, genes included in the WS deletion could directly affect amygdala or frontal cortex systems that support the detection of emotion in faces. Reduced activation of the amygdala has been reported in people with WS compared with controls when they view negative affect faces, and atypical morphology of the amygdala has been reported in MRI and post-mortem studies [10, 58]. These behavioral, functional, and anatomical findings could be explained by reduced syntaxin 1-a (STX1A) expression. STX1A, a deleted gene centromeric to the elastin gene and thought to be involved in pre-synaptic release of neurotransmitter [59], is expressed prenatally in normal human amygdala tissue [60].

There is one additional explanation for the social-emotional problems observed in people with WS. A recent study of face approachability surprisingly demonstrated that people with WS were more likely to give negative ratings to less approachable faces than control subjects [61]. The authors suggested that people with WS can detect negative affect faces but that they cannot inhibit an approach response. People with WS show a strong appetitive drive for social interaction as manifested, for example, by indiscriminately approaching strangers [62]. In addition, people with WS exhibit an aberrant developmental course of social engagement. Sociability increases for all groups of children until the age of seven, at which time sociability decreases in the control groups but remains elevated in children with WS [4]. These ob-

servations suggest that impaired executive system development results in the aberrant social behavior observed in people with WS.

A study by Meyer-Lindenberg et al. [29] also supports the notion for impaired executive system development in people with WS. Meyer-Lindenberg et al. [29?] presented evidence indicating that depressed amygdala activation to faces was related to reduced orbitofrontal cortex activation, and suggested there was dysregulation of frontal systems on the amygdala. While it is plausible that diminished parietal input into frontal executive systems disrupts executive system representations, specific effects of the WS deletion on frontal systems regulating emotion provides a simpler explanation for the social emotional problems in people with WS.

## Language

The language of people with WS has generated considerable interest because of the relative strength of different language domains, particularly expressive language, in comparison to people with Down's syndrome or to their own visual spatial deficits [8, 63]. WS language development provides an interesting window into the consequences of having deficits in frontal executive function and/or deficits in visual system function.

Emotion appears to play an important role in the relative language strengths in people with WS. WS speech is fluent and often contains prosody and words that enrich the affective quality of their speech [64]. Pearlman-Avni and Eviatar [65] suggested that the relatively strong WS speech performance is specific to emotion-related language. While there are no functional imaging studies examining the interaction of language and emotion in WS, there is human post-mortem histological evidence for increased limbic input into the auditory cortex [66].

WS language is far from normal, however. For example, language deficits have been observed in the domains of irregular inflection [67] and relative clauses [68]. In addition, there is evidence for word comprehension deficits when the speech is spatially related [69]. This is an example of how diminished spatial representations can have an induced effect on the development and function of language.

With the exception of one electrophysiological study [49], there are few electrophysiological or fMRI experiments that have explicitly examined language function in people with WS. The one electrophysiological study demonstrated exaggerated left temporal responses to semantic anomalies in WS compared with that in control participants. In addition, WS participants did not exhibit response differences to open *versus* closed class words that are observed in normal participants [49]. These find-

ings suggest the presence of anomalous language organization or impaired interpretation of the language stimuli in WS.

Three studies have examined the morphology of the planum temporale in WS to determine if altered hemispheric asymmetry of this region might play a role in anomalous language organization. A structural MRI study of WS reported that three of four people with WS had prominent leftward planum temporale asymmetry that was equivalent in degree to musicians with perfect pitch [70]. In contrast, a post-mortem study reported planum temporale symmetry in two of four WS brains [58]. This discrepancy could be due to small samples or methodological differences. A larger study of 42 WS participants and 40 controls showed that a few WS cases had extreme leftward asymmetry, but as a group the WS participants exhibited significantly less leftward asymmetry due to large right plana temporale [17]. In a subset of subjects, the right planum was enlarged because the Sylvian fissure remained horizontal and failed to make its normal vertical bend into the right hemisphere parietal lobe. This observation may relate to auditory and language organization. We predict this finding reflects anomalous fiber connectivity of temporal and parietal regions in the right hemisphere.

## Summary

Studies of WS demonstrate striking concordance between the cognitive and behavioral impairments that define the disorder and neurobiological anomalies in regions that normally subserve those functions. These findings are surprisingly consistent across studies employing different methodologies and sample sizes. There is no question that people with WS demonstrate anomalous dorsal stream morphology and function. Questions remain about which deleted gene(s) contribute to these findings. The evidence reviewed above suggests that some of the language-related behavioral and anatomical findings might be a consequence of early developmental impairments in dorsal stream systems. The social emotional behavior in people with WS largely appears to be of distinct neurobiological origin, however [41]. The section below presents testable hypotheses that provide a foundation for understanding the development of impaired visual-motor systems.

## The developmental neurobiology of dorsal stream impairment

Genetic studies of WS have identified target genes for the cognitive and behavioral impairments observed in people with WS. Deleted genes centromeric to the elastin gene

(cytoplasmic linker protein 2; Frizzled 9) and telomeric to the elastin gene (TFII-I genes, GTF2I and GTFIRD1) probably have direct effects and/or interact with other genes to have widespread effects on the WS neurobiological profile at multiple stages in life. Recent case studies of people with atypical deletions suggest that the TFII-I genes have dosage-dependent influences on the development of craniofacial and neurological systems [71]. More specifically, hemizygosity for these genes appears to be associated with greater cognitive and behavioral impairments [71]. The TFII-I gene family's regulation of gooseoid suggests that variation in TFII-I gene family expression could modulate patterning of posterior cortex. While we are not aware of evidence that gooseoid expression is regulated by TFII-I genes specifically in the posterior cortex, there is human post-mortem evidence for reduced GTF2I expression in primary visual cortex [72].

Despite the strong evidence for the TFII-I gene family as having a specific role in the atypical WS cognitive and behavioral development, there are studies of atypical deletions cases indicating that LIM-kinase 1 (LIMK1) hemizygosity contributes to WS visual spatial deficits [73]. In light of the TFII-I gene family findings, we suggest that LIMK1 hemizygosity may exacerbate the visual-motor impairments in WS.

Although preliminary, we present two developmental hypotheses for the visual-motor impairments in WS. These hypotheses focus on LIMK1 because of evidence from atypical WS deletion cases implicating LIMK1 in cognitive deficits [9], and the well-understood functional roles for LIMK1 that could affect neuronal migration and synaptogenesis in WS. Both hypotheses include mechanisms that could have direct effects on the visual-motor system. These hypotheses can potentially be tested by utilizing mouse knockout studies and analyzing post-mortem histology from individuals with WS.

We propose that LIMK1 hemizygosity affects the development of posterior thalamic regions that project to visual cortex. This hypothesis is based on the behavioral, structural, and functional evidence reviewed above that indicates anomalous visual motor system development in WS. In addition, some of the social-emotional and language problems in WS could relate to atypical pulvinar development since the pulvinar supports implicit face affect detection [57] and language function [74, 75].

LIMK1 is involved in lamellipodia extension and retraction in migrating neurons [76], and abnormal LIMK1 expression levels negatively influence neuronal growth cone extension and retraction [76, 77]. We suggest that LIMK1 hemizygosity particularly affects posterior thalamus neurons because of a potential role in the migration of neurons to the diencephalon. Impaired posterior thalamus development could affect function throughout the visual-motor system and produce the range of visual system impairments observed in people with WS.

Brain regions such as the posterior thalamus, caudate, and amygdala receive neurons from a ventral telencephalic proliferative zone. This proliferative zone is distinct from the ventricular proliferative zone that contributes most of the neurons to the cortex. This ventral telencephalic proliferative zone is called the ganglionic eminence. It is a C-shaped developmental structure adjacent to the caudate and walls of the lateral ventricle [78, 79]. Based on findings such as the marked loss of gray matter in the posterior thalamus, we hypothesize that LIMK1 hemizygosity affects the migration of ganglionic eminence neurons to the posterior thalamus.

The medial, lateral, and caudal ganglionic eminences populate different regions of the mouse brain with GABAergic interneurons [80]. For example, medial ganglionic eminence neurons migrate to the striatum, thalamus, and cortex [78], while the caudal ganglionic eminence contributes neurons to the amygdala [81]. Each region of the ganglionic eminence appears to be genetically distinct based on studies of knockout of homeobox precursors (e.g. *Nkx2.1*) that decrease medial ganglionic eminence interneurons and increase the size of the lateral ganglionic eminence [82].

Medial ganglionic eminence neurons express the erbB4 neuregulin receptor in the mouse [83]. Neuregulin interacts with LIMK1 [84], and may be part of LIMK1-cofilin signaling pathway that is critical to neuronal migration [76]. To our knowledge there are no reports directly implicating LIMK1 in the migration of medial ganglionic eminence neurons. It is intriguing to think, however, that LIMK1 is critical to the migration of posterior thalamus during a second phase of development that is unique to humans [85, 86]. Figure 2 shows a dramatic decrease in posterior thalamus gray matter volume, indicating anomalous development of the pulvinar in WS.

This LIMK1-pulvinar hypothesis has limitations, however. Neuronal migration impairments would be expected to produce ectopic neurons, and no study has reported ectopic neurons in post-mortem WS brains. Studies of post-mortem human brain tissue could test the LIMK1-pulvinar hypothesis by determining whether posterior thalamic neurons exhibit disorganized cytoarchitecture.

An alternative and simpler explanation for the WS neurobiological pattern is that a reduction in dendritic branching limits the number of posterior parietal targets for occipital and thalamic projections. LIMK1 also is important for dendritic morphogenesis [87] and synapse formation in mice [88], because it contributes to the development and maintenance of actin cytoskeleton through its association with cofilin, an actin binding protein [89]. A reduction in parietal dendritic branching also could affect function throughout the visual-motor system and produce the range of visual system impairments observed in people with WS.

Reduced dendritic branching is one explanation for the decreased neuropil and brain volume observed in WS, particularly in the superior parietal lobule [34]. This idea is supported by findings of abnormal dendritic spine morphology and synapse formation in hippocampus of LIMK knockout mice. Behaviorally, these mice exhibit spatial learning deficits and enhanced freezing in response to a tone that was conditioned with a foot shock [90]. Pharmacological treatments that enhance the stability of spine morphology could be one way to improve the cognitive and behavioral function of people with WS. This idea is very preliminary, however, and requires evidence for abnormal spine morphology in humans with WS.

## Conclusions

The confluence of behavioral and neurobiological findings to date suggests that the visual-motor system is particularly affected in people with WS. One question we asked in this review was whether primary visual system impairment could have downstream consequences on neural systems that support social-emotional and language function. Behaviorally, difficulty with spatial language could stem from visual system impairments. Anatomically, atypical Sylvian fissure patterning could reflect atypical parietal lobe development and fiber projections from the visual system to social-emotional and language systems. Many other WS findings, however, appear more likely to reflect direct or indirect genetic effects of the WS deletion. We predict that TFII-I (GTF2I and GTF2IRD1) hemizyosity affect patterning of posterior cortex and LIMK1 hemizyosity may affect neuronal migration to the posterior thalamus and/or dendritic arborization in WS. Early childhood longitudinal, atypical deletion, human post-mortem, and mouse knockout studies will be critical for determining the specific roles of the deleted genes on WS brain development.

*Acknowledgement.* We would like to thank Christiana Leonard for her thoughtful comments. We also thank the NICHD (P01 HD33113) and the National Center for Research Resources (C06 RR014516) for supporting this research.

- Cherniske, E. M., Carpenter, T. O., Klaiman, C., Young, E., Bregman, J., Insogna, K., Schultz, R. T. and Pober, B. R. (2004) Multisystem study of 20 older adults with Williams syndrome. *Am. J. Med. Genet.* 131A, 255–264.
- Korenberg, J. R., Chen, X. N., Hirota, H., Lai, Z., Bellugi, U., Burian, D., Roe, B. and Matsuoaka, R. (2000) VI. Genome structure and cognitive map of Williams syndrome. *J. Cogn. Neurosci.* 12 Suppl. 1, 89–107.
- Atkinson, J., King, J., Braddick, O., Nokes, L., Anker, S. and Braddick, F. (1997) A specific deficit of dorsal stream function in Williams' syndrome. *Neuroreport* 8, 1919–1922.
- Doyle, T. F., Bellugi, U., Korenberg, J. R. and Graham, J. (2004) 'Everybody in the world is my friend' hypersociability in young children with Williams syndrome. *Am. J. Med. Genet. A* 124, 263–273.
- Dykens, E. M. (2003) Anxiety, fears, and phobias in persons with Williams syndrome. *Dev. Neuropsychol.* 23, 291–316.
- Gothelf, D., Farber, N., Raveh, E., Apter, A. and Attias, J. (2006) Hyperacusis in Williams syndrome: Characteristics and associated neuroaudiological abnormalities. *Neurology* 6, 390–395.
- Atkinson, J., Anker, S., Braddick, O., Nokes, L., Mason, A. and Braddick, F. (2001) Visual and visuospatial development in young children with Williams syndrome. *Dev. Med. Child Neurol.* 43, 330–337.
- Bellugi, U., Lichtenberger, L., Jones, W., Lai, Z. and St George, M. (2000) I. The neurocognitive profile of Williams syndrome: a complex pattern of strengths and weaknesses. *J. Cogn. Neurosci.* 12 Suppl 1, 7–29.
- Frangiskakis, J. M. et al. (1996) LIM-kinase I hemizyosity implicated in impaired visuospatial constructive cognition. *Cell* 86, 59–69.
- Reiss, A., Eckert, M. A., Rose, F. E., Karchemskiy, A., Kesler, S., Chang, M., Reynolds, M. F., Kwon, H. and Galaburda, A. (2004) An experiment of nature: brain anatomy parallels cognition and behavior in Williams syndrome. *J. Neurosci.* 24, 5009–5015.
- Thompson, P., Lee, A. D., Dutton, R. A., Geaga, J. A., Hayashi, K. M., Eckert, M. A., Bellugi, U., Galaburda, A. M., Korenberg, J. R., Mills, D. L., Toga, A. W. and Reiss, A. L. (2005) Abnormal cortical complexity and thickness profiles mapped in Williams syndrome. *J. Neurosci.* 25, 4146–4158.
- Jernigan, T. L. and Bellugi, U. (1990) Anomalous brain morphology on magnetic resonance images in Williams syndrome and Down syndrome. *Arch. Neurol.* 47, 529–533.
- Bishop, K. M., Goudreau, G. and O'Leary, D. D. (2000) Regulation of area identity in the mammalian neocortex by Emx2 and Pax6. *Science* 288, 344–349.
- Ku, M., Sokol, S., Wu, J., Tussie-Luna M Roy, A. and Hata A. (2005) Positive and negative regulation of the transforming growth factor beta/activin target gene goosecoid by the TFII-I family of transcription factors. *Mol. Cell. Biol.* 25, 7144–7157.
- Galaburda, A. M., Schmitt, J. E., Atlas, S. W., Eliez, S., Bellugi, U. and Reiss, A. L. (2001) Dorsal forebrain anomaly in Williams syndrome. *Arch. Neurol.* 58, 1865–1869.
- Jackowski, A. P. and Schulz, R. T. (2005) Foreshortened dorsal extension of the central sulcus in Williams syndrome. *Cortex* 41, 282–290.
- Eckert, M. A., Galaburda, A. G., Karchemskiy, A. and Liang, A., Thompson, P., Dutton, R., Lee, A., Bellugi, U., Korenberg, J. R., Mills, D., Rose, F. and Reiss, A. L. (submitted) Anomalous Sylvian fissure morphology in Williams syndrome. *Neuroimage*.
- Schmitt, J. E., Watts, K., Eliez, S., Bellugi, U., Galaburda, A. M. and Reiss, A. L. (2002) Increased gyrification in Williams syndrome: evidence using 3D MRI methods. *Dev. Med. Child Neurol.* 44, 292–295.
- Faravelli, F., D'Arrigo, S., Bagnasco, I., Selicorni, A., D'Incerti, L., Riva, D. and Pantaleoni, C. (2003) Oligogyric microcephaly in a child with Williams syndrome. *Am. J. Med. Genet. A* 117, 169–171.
- Brinkmann, G., Heller, M., Partsch, C. J., Gosch, A. and Pankau, R. (1997) Magnetic resonance imaging of the brain in Williams-Beuren syndrome. *Am. J. Med. Genet.* 68, 243.
- Schmitt, J. E., Eliez, S., Bellugi, U. and Reiss, A. L. (2001) Analysis of cerebral shape in Williams syndrome. *Arch. Neurol.* 58, 283–287.
- Schmitt, J. E., Eliez, S., Warsofsky, I. S., Bellugi, U. and Reiss, A. L. (2001) Corpus callosum morphology of Williams syndrome: relation to genetics and behavior. *Dev. Med. Child Neurol.* 43, 155–159.
- Tomaiuolo, F., Di Paola, M., Caravale, B., Vicari, S., Petrides, M. and Caltagirone, C. (2002) Morphology and morphometry of the corpus callosum in Williams syndrome: a T1-weighted MRI study. *Neuroreport* 13, 2281–2284.

- 24 Farran, E. K., Jarrold, C. and Gathercole, S. E. (2003) Divided attention, selective attention and drawing: processing preferences in Williams syndrome are dependent on the task administered. *Neuropsychologia* 41, 676–687.
- 25 Scerif, G., Cornish, K., Wilding, J., Driver, J. and Karmiloff-Smith, A. (2004) Visual search in typically developing toddlers and toddlers with Fragile X or Williams syndrome. *Dev. Sci.* 7, 116–130.
- 26 van der Geest, J. N., Lagers-van Haselen, G. C., van Hagen, J. M., Govaerts, L. C., de Coo, I. F., de Zeeuw, C. I. and Frens, M. A. (2004) Saccade dysmetria in Williams-Beuren syndrome. *Neuropsychologia* 42, 569–576.
- 27 Paul, B. M., Stiles, J., Passarotti, A., Bavar, N. and Bellugi, U. (2002) Face and place processing in Williams syndrome: evidence for a dorsal-ventral dissociation. *Neuroreport* 13, 1115–1119.
- 28 Mobbs, D., Garrett, A. S., Menon, V., Rose, F., Bellugi, U. and Reiss, A. L. (2004) Anomalous brain activation during face and gaze processing in Williams syndrome. *Neurology* 62, 2070–2076.
- 29 Meyer-Lindenberg, A., Kohn, P., Mervis, C. B., Kippenhan, J. S., Olsen, R. K., Morris, C. A. and Berman, K. F. (2004) Neural basis of genetically determined visuospatial construction deficit in Williams syndrome. *Neuron* 43, 623–631.
- 30 Mobbs, D., Eckert, M. A., Menon, V., Bellugi, U., Galaburda, A. G., Korenberg, J. R., Mills, D., Rose, F. and Reiss, A. L. (2004) Genes, neural systems, and cognition: GTF2I and GTF2IRD1 linked to Williams syndrome: Parietal lobe activation and visuospatial working memory. Society for Neuroscience Annual Meeting 2004 Abstracts.
- 31 Van Essen, D., Raichle, M., Rose, F. and Bellugi, U. (2004) Differences in cortical shape in Williams syndrome subjects compared with normal humans revealed by surface-based analysis. Society for Neuroscience Annual Meeting 2004 Abstracts.
- 32 Kippenhan, J. S., Olsen, R. K., Mervis, C. B., Morris, C. A., Kohn, P., Meyer-Lindenberg, A. and Berman, K. F. (2005) Genetic contributions to human gyrification: sulcal morphometry in Williams syndrome. *J. Neurosci.* 25, 7840–7846.
- 33 Eckert, M. A., Hu, D., Eliez, S., Bellugi, U., Galaburda, A., Korenberg, J., Mills, D. and Reiss, A. L. (2005) Evidence for superior parietal impairment in Williams syndrome. *Neurology* 64, 152–153.
- 34 Holinger, D. P., Sherman, G. F., McMenamin, D., Bellugi, U. and Galaburda, A. M. (2002) Postmortem neuronal measures in area 7 of the parietal lobe in Williams syndrome. Society for Neuroscience Annual Meeting Abstracts, p. 402.4.
- 35 Ellermann, J. M., Siegal, J. D., Strupp, J. P., Ebner, T. J. and Ugurbil, K. (1998) Activation of visuomotor systems during visually guided movements: a functional MRI study. *J. Magn. Reson.* 131, 272–285.
- 36 Denny-Brown, D. and Fischer, E. G. (1976) Physiological aspects of visual perception. II. The subcortical visual direction of behavior. *Arch. Neurol.* 33, 228–242.
- 37 Ward, R., Danziger, S., Owen, V. and Rafal, R. (2002) Deficits in spatial coding and feature binding following damage to spatiotopic maps in the human pulvinar. *Nat Neurosci* 5, 99–100.
- 38 Molotchnikoff, S. and Shumikhina, S. (1996) The lateral posterior-pulvinar complex modulation of stimulus-dependent oscillations in the cat visual cortex. *Vision Res.* 36, 2037–2046.
- 39 Shumikhina, S. and Molotchnikoff, S. (1999) Pulvinar participates in synchronizing neural assemblies in the visual cortex, in cats. *Neurosci. Lett.* 272, 135–139.
- 40 Grice, S. J., Spratling, M. W., Karmiloff-Smith, A., Halit, H., Csibra, G., de Haan, M. and Johnson, M. H. (2001) Disordered visual processing and oscillatory brain activity in autism and Williams syndrome. *Neuroreport* 12, 2697–2700.
- 41 Eckert, M. A., Tenforde, A., Galaburda, A., Mills, D., Korenberg, J. and Reiss, A. L. (in press) To modulate or not to modulate: Differing results in uniquely shaped Williams syndrome brains. *Neuroimage*.
- 42 Takagi, M., Zee, D. S. and Tamargo, R. J. (1998) Effects of lesions of the oculomotor vermis on eye movements in primate: saccades. *J. Neurophysiol.* 80, 1911–1931.
- 43 Noda, H. and Fujikado, T. (1987) Topography of the oculomotor area of the cerebellar vermis in macaques as determined by microstimulation. *J. Neurophysiol.* 58, 359–378.
- 44 Jones, W., Hesselink, J., Courchesne, E., Duncan, T., Matsuda, K. and Bellugi, U. (2002) Cerebellar abnormalities in infants and toddlers with Williams syndrome. *Dev. Med. Child Neurol.* 44, 688–694.
- 45 Reiss, A. L., Eliez, S., Schmitt, J. E., Straus, E., Lai, Z., Jones, W. and Bellugi, U. (2000) IV. Neuroanatomy of Williams syndrome: a high-resolution MRI study. *J. Cogn. Neurosci.* 12 Suppl. 1, 65–73.
- 46 Schmitt, J. E., Eliez, S., Warsofsky, I. S., Bellugi, U. and Reiss, A. L. (2001) Enlarged cerebellar vermis in Williams syndrome. *J. Psychiatr. Res.* 35, 225–229.
- 47 Wang, P. P., Hesselink, J. R., Jernigan, T. L., Doherty, S. and Bellugi, U. (1992) Specific neurobehavioral profile of Williams' syndrome is associated with neocerebellar hemispheric preservation. *Neurology* 42, 1999–2002.
- 48 Galaburda, A. M., Holinger, D. P., Bellugi, U. and Sherman, G. F. (2002) Williams syndrome: neuronal size and neuronal-packing density in primary visual cortex. *Arch. Neurol.* 59, 1461–1467.
- 49 Bellugi, U., Lichtenberger, L., Mills, D., Galaburda, A. and Korenberg, J. R. (1999) Bridging cognition, the brain and molecular genetics: evidence from Williams syndrome. *Trends Neurosci.* 22, 197–207.
- 50 Mills, D. L., Alvarez, T. D., St George, M., Appelbaum, L. G., Bellugi, U. and Neville, H. (2000) III. Electrophysiological studies of face processing in Williams syndrome. *J. Cogn. Neurosci.* 12 Suppl. 1, 47–64.
- 51 Thomas, M., Annaz, D., Humphreys, K., Ewing, S., Brace, N., Duuren, M., Pike, G., Grice, S. and Campbell, R. (2004) Exploring the Williams syndrome face-processing debate: the importance of building developmental trajectories. *J. Child Psychol. Psychiatry* 45, 1258–1274.
- 52 Deruelle, C., Mancini, J., Livet, M. O., Casse-Perrot, C. and de Schonen, S. (1999) Configural and local processing of faces in children with Williams syndrome. *Brain Cogn.* 41, 276–298.
- 53 Plesa-Skwerer, D., Faja, S., Schofield, C., Verbalis, A. and Tager-Flusberg, H. (2006) Perceiving facial and vocal expressions of emotion in individuals with Williams syndrome. *Am. J. Ment. Retard.* 111, 15–26.
- 54 Whalen, P., Kagan, J., Cook, R., Davis, F., Kim, H., Polis, S., McLaren, D., Somerville, L., McLean, A., Maxwell, J. and Johnstone, T. (2004) Human amygdala responsivity to masked fearful eye whites. *Science* 306, 2061.
- 55 Tipples, J., Atkinson, A. P. and Young, A. W. (2002) The eyebrow frown: A salient social signal. *Emotion* 2, 288–296.
- 56 Kohler, C., Turner, T., Stolar, N., Bilker, W., Bressinger, C., Gur, R. and Gur, R. (2004) Differences in facial expressions of four universal emotions. *Psychiatry Res.* 128, 235–244.
- 57 Vuilleumier, P., Armony, J. L., Driver, J. and Dolan, R. J. (2003) Distinct spatial frequency sensitivities for processing faces and emotional expressions. *Nat. Neurosci.* 6, 624–631.
- 58 Galaburda, A. M. and Bellugi, U. (2000) V. Multi-level analysis of cortical neuroanatomy in Williams syndrome. *J. Cogn. Neurosci.* 12 Suppl. 1, 74–88.
- 59 Sudhof, T. C. (1995) The synaptic vesicle cycle: A cascade of protein-protein interactions. *Nature* 375, 645–653.
- 60 Botta, A., Sanguuolo, F., Calza, L., Giardino, L., Potenza, S., Novelli, G. and Dallapiccola, B. (1999) Expression analysis and protein localization of the human HPC-1/syntaxin 1A, a gene deleted in Williams syndrome. *Genomics* 62, 525–528.
- 61 Frigerio, E., Burt, D., Gagliardi, C., Cioffi, G., Martelli, S., Perrett, D. and Borgatti, R. (2006) Is everybody always my friend?



- Perception of approachability in Williams syndrome. *Neuropsychologia* 44, 254–259.
- 62 Bellugi, U., Adolphs, R., Cassady, C. and Chiles, M. (1999) Towards the neural basis for hypersociability in a genetic syndrome. *Neuroreport* 10, 1653–1657.
- 63 Mervis, C. B. and Robinson, B. F. (2000) Expressive vocabulary ability of toddlers with Williams syndrome or Down syndrome: a comparison. *Dev. Neuropsychol.* 17, 111–126.
- 64 Reilly, J., Klima, E. S., Bellugi, U. (1990) Once more with feeling: Affect and language in children from atypical populations. *Dev. Psychopathol.* 2, 367–392.
- 65 Pearlman-Avniot, S. and Eviatar, Z. (2002) Narrative analysis in developmental social and linguistic pathologies: dissociation between emotional and informational language use. *Brain Cogn.* 48, 494–499.
- 66 Holinger, D. P., Bellugi, U., Mills, D. L., Korenberg, J. R., Reiss, A. L., Sherman, G. F. and Galaburda, A. M. (2005) Relative sparing of primary auditory cortex in Williams syndrome. *Brain Res.* 1037, 35–42.
- 67 Clahsen, H. and Almazan, M. (1998) Syntax and morphology in Williams syndrome. *Cognition* 68, 167–198.
- 68 Grant, J., Valian, V. and Karmiloff-Smith, A. (2002) A study of relative clauses in Williams syndrome. *J. Child Lang.* 29, 403–416.
- 69 Phillips, C. E., Jarrold, C., Baddeley, A. D., Grant, J. and Karmiloff-Smith, A. (2004) Comprehension of spatial language terms in Williams syndrome: evidence for an interaction between domains of strength and weakness. *Cortex* 40, 85–101.
- 70 Hickok, G., Bellugi, U. and Jones, W. (1995) Asymmetrical ability. *Science* 270, 219–220.
- 71 Tassabehji, M., Hammond, P., Karmiloff-Smith, A., Thompson, P., Thorgerisson, S., Durkin, M., Popescu, N., Hutton, T., Metcalfe, K., Rucka, A., Stewart, H., Read, A., Maconochie, M. and Donnai, D. (2005) GTF2IRD1 in craniofacial development of humans and mice. *Science* 310, 1184–1187.
- 72 Galaburda, A. M., Holinger, D. P., Korenberg, J. R., Itoka, P. and Bellugi, U. (2002) in: GTF21 Immunostaining in area 17 in Williams Syndrome. Society for Neuroscience Annual Meeting 2002 Abstracts, p. 402.3.
- 73 Gray, V., Karmiloff-Smith, A., Funnell, E. and Tassabehji, M. (2006) In-depth analysis of spatial cognition in Williams syndrome: A critical assessment of the role of the LIMK1 gene. *Neuropsychologia* 44, 679–685.
- 74 Lockwood, A. H., Murphy, B. W. and Khalak, H. (1997) Attentional systems and the allocation of cerebral resources in reading and grammatical tasks. *Int. J. Neurosci.* 91, 241–252.
- 75 Nadeau, S. E., Crosson, B. (1997) Subcortical Aphasia. *Brain Lang.* 58, 355–402.
- 76 Nagata-Ohashi, K., Ohta, Y., Goto, K., Chiba, S., Mori, R., Nishita, M., Ohashi, K., Kousaka, K., Iwamatsu, A., Niwa, R., Uemura, T. and Mizuno, K. (2004) A pathway of neuregulin-induced activation of cofilin-phosphatase Slingshot and cofilin in lamellipodia. *J. Cell Biol.* 165, 465–471.
- 77 Birkenfeld, J., Betz, H. and Roth, D. (2001) Inhibition of neurite extension by overexpression of individual domains of LIM kinase 1. *J. Neurochem.* 78, 924–927.
- 78 Parnavelas, J. G. (2000) The origin and migration of cortical neurones: new vistas. *Trends Neurosci.* 23, 126–131.
- 79 Ulfing, N. (2002) Ganglionic eminence of the human fetal brain – new vistas. *Anat. Rec.* 267, 191–195.
- 80 Brazel, C. Y., Romanko, M. J., Rothstein, R. P. and Levison, S. W. (2003) Roles of the mammalian subventricular zone in brain development. *Prog. Neurobiol.* 69, 49–69.
- 81 Ulfing, N., Setzer, M. and Bohl, J. (2003) Ontogeny of the human amygdala. *Ann. N. Y. Acad. Sci.* 985, 22–33.
- 82 Sussel, L., Marin, O., Kimura, S. and Rubenstein, J. L. (1999) Loss of Nkx2.1 homeobox gene function results in a ventral to dorsal molecular respecification within the basal telencephalon: evidence for a transformation of the pallidum into the striatum. *Development* 126, 3359–3370.
- 83 Yau, H. J., Wang, H. F., Lai, C. and Liu, F. C. (2003) Neural development of the neuregulin receptor ErbB4 in the cerebral cortex and the hippocampus: preferential expression by interneurons tangentially migrating from the ganglionic eminences. *Cereb. Cortex* 13, 252–264.
- 84 Wang, J. Y., Frenzel, K. E., Wen, D. and Falls, D. L. (1998) Transmembrane neuregulins interact with LIM kinase 1, a cytoplasmic protein kinase implicated in development of visuospatial cognition. *J. Biol. Chem.* 273, 20525–20534.
- 85 Letinic, K. and Rakic, P. (2001) Telencephalic origin of human thalamic GABAergic neurons. *Nat. Neurosci.* 4, 931–936.
- 86 Rakic, P. and Sidman, R. L. (1969) Telencephalic origin of pulvinar neurons in the fetal human brain. *Z. Anat. Entwicklungsgesch.* 129, 53–82.
- 87 Meng, Y., Zhang, Y., Tregoubov, V., Falls, D. L. and Jia, Z. (2003) Regulation of spine morphology and synaptic function by LIMK and the actin cytoskeleton. *Rev. Neurosci.* 14, 233–240.
- 88 Sarmiere, P. D. and Bamberg, J. R. (2002) Head, neck, and spines: a role for LIMK-1 in the hippocampus. *Neuron* 35, 3–5.
- 89 Yang, N., Higuchi, O., Ohashi, K., Nagata, K., Wada, A., Kangawa, K., Nishida, E. and Mizuno, K. (1998) Cofilin phosphorylation by LIM-kinase 1 and its role in Rac-mediated actin reorganization. *Nature* 393, 809–812.
- 90 Meng, Y., Zhang, Y., Tregoubov, V., Janus, C., Cruz, L., Jackson, M., Lu, W. Y., MacDonald, J. F., Wang, J. Y., Falls, D. L. and Jia, Z. (2002) Abnormal spine morphology and enhanced LTP in LIMK-1 knockout mice. *Neuron* 35, 121–133.

